



ASSESSMENT OF THE EFFICIENCY OF CONSERVATIVE TREATMENT OF PEYRONIE'S DISEASE

© S.N. Kalinina¹, V.N. Fesenko¹, A.V. Nikolskii², O.O. Burlaka², N.V. Marchenko²

¹ North-Western State Medical University named after I.I. Mechnikov, Saint Petersburg, Russia;

² Aleksandrovskaya Hospital, Saint Petersburg, Russia

For citation: Kalinina SN, Fesenko VN, Nikolskii AV, et al. Assessment of the efficiency of conservative treatment of Peyronie's disease. *Urologicheskie vedomosti*. 2018;8(1):5-10. doi: 10.17816/uroved815-10

Received: 22.01.2018

Accepted: 06.03.2018

There were 27 men under observation who got conservative treatment for Peyronie's disease. The criteria for inclusion in the study were the maximum size of the plaque of the penis up to 1.5 cm and the angle of curvature of the penis is less than 45 degrees. Before treatment, after 6 and 12 months, patients underwent ultrasonic dopplerography of the penis, the velocity of blood flow in the cavernous and dorsal arteries and the size of the plaque were determined. All observed patients were prescribed combined therapy, such as symptomatic, immunological and physiotherapeutic treatment. In this case, the patients of the 1st group ($n = 15$) additionally got longidase treatment (intramuscularly for 3000 IU every 3 days, for a course of 10 injections with concurrent administration of rectal suppositories with longidase at the same dose for a course of 10 suppositories). Locally, these patients were assigned phonophoresis with longidase on the plaque area (10 sessions). The remaining 12 patients (2nd group) didn't get longidase treatment. Six months after the start of treatment the absence of plaques was recorded in 8 (53.3%) patients in the 1st group and 4 (33.3%) in the 2nd group of patients and in 12 months in 11 (73.3%) and 6 (41.6%) patients. Thus, conservative therapy in Peyronie's disease is effective in patients in the early stages of the disease with moderate deviation of the penis and plaques up to 1.5 cm. The inclusion of longidase in the complex therapy increases the effectiveness of the treatment.

Keywords: Peyronie's disease; longidase; erectile dysfunction; ultrasonic dopplerography of the penis.

ОЦЕНКА ЭФФЕКТИВНОСТИ КОНСЕРВАТИВНОГО ЛЕЧЕНИЯ БОЛЕЗНИ ПЕЙРОНИ

© С.Н. Калинина¹, В.Н. Фесенко¹, А.В. Никольский², О.О. Бурлака², Н.В. Марченко²

¹ ФГБОУ ВО «Северо-Западный государственный медицинский университет им. И.И. Мечникова» Минздрава России, Санкт-Петербург;

² СПб ГБУЗ «Александровская больница», Санкт-Петербург

Для цитирования: Калинина С.Н., Фесенко В.Н., Никольский А.В., и др. Оценка эффективности консервативного лечения болезни Пейрони // Урологические ведомости. – 2018. – Т. 8. – № 1. – С. 5–10. doi: 10.17816/uroved815-10

Дата поступления: 22.01.2018

Статья принята к печати: 06.03.2018

Под наблюдением находились 27 мужчин, получавших консервативное лечение по поводу болезни Пейрони. Критериями включения в исследование были максимальный размер бляшки полового члена до 1,5 см и угол искривления полового члена менее 45 градусов. До начала лечения, через 6 и 12 месяцев больным выполняли ультразвуковую доплерографию полового члена, при которой определяли скорость кровотока в кавернозных и дорсальных артериях и размеры бляшки. Всем наблюдаемым больным назначали комбинированную терапию — симптоматическое, иммунологическое и физиотерапевтическое лечение. При этом пациенты 1-й группы ($n = 15$) дополнительно получали препарат лонгидазу (внутримышечно по 3000 МЕ 1 раз в 3 дня, на курс 10 инъекций с одновременным введением ректально свечей с лонгидазой в той же дозе, на курс 10 свечей). Локально этим пациентам назначали фонофорез с лонгидазой на область бляшек (10 сеансов). Остальные 12 больных (2-я группа) препарат лонгидазу не получали. Через 6 месяцев после начала лечения отсутствие бляшек зафиксировано у 8 (53,3 %) больных 1-й группы и 4 (33,3 %) больных 2-й группы, а через 12 месяцев — соответственно у 11 (73,3 %) и 6 (41,6 %) пациентов. Таким образом, консервативная терапия при болезни Пейрони

эффективна у пациентов на ранних стадиях заболевания, при умеренной девиации полового члена и размерах бляшек до 1,5 см. Включение в комплексную терапию препарата лонгидаза повышает эффективность проводимого лечения.

⊗ **Ключевые слова:** болезнь Пейрони; лонгидаза; эректильная дисфункция; ультразвуковая доплерография полового члена.

Peyronie's disease or penile fibromatosis has become one of the most significant problems in men's health in recent decades. Peyronie's disease does not pose a suffer to the life of the patient, but it interferes with the sexual life of men, leads to sexual insufficiency, disrupts the family and causes severe depression.

Peyronie's disease was first described in 1743 by François de la Peyronie (1678–1747) the court surgeon of King Louis XV of France. Even though 275 years have passed there is currently no consensus on the causes of Peyronie's disease because its etiology and pathogenesis are still not fully clear [1, 2]. There are also disputes about the terminology used to describe the disease. In several cases, penile fibromatosis is defined as a disease with a predominant localization of the pathological process in the cavernous bodies of the penis and leads to penile deformity during erection. In other studies it is defined as the gradual and mildly painful induration of several sections of cavernous bodies and the formation of dense connective tissue plaques, which lead to the functional abnormality of the penis. Peyronie's disease is sometimes defined as a benign slowly progressing disease with an unclear etiology and is characterized by the formation of fibrous extracavernous plaques on the tunica albuginea of the penis, thus leading to phallosclerosis and abnormal erectile function. Several studies indicate that Peyronie's disease is a focal fibrosis (scarring) of the tunica albuginea of the penis, which leads to a distortion of the ratio of collagen and elastic fibers, a disorder of the elasticity of the tunica albuginea and phallosclerosis during erection to the side where the tunica albuginea is not impaired. At the last revision of ICD-10 in 2005, Peyronie's disease and penile fibrous cavernous bodies were combined into one nosological group related to penile fibromatosis.

To date, the prevalence of Peyronie's disease is estimated to be in the range of 3% to 8% in all men [3–5]. The disease may not always be accompanied by clinical symptomatology that requires treatment. The incidence of penile fibromatosis increases with the increasing age of the patient [1]. This may be a result of the decreased elasticity of penile tissues in older men, which increases the risk of microinjuries in penile tissues. The most

common theories about how Peyronie's disease develops include the following [6, 7]:

1. Microinjuries of the tunica albuginea of the penis: an insignificant tearing of the tunica albuginea with the formation of a small hematoma causes fibrin to activate fibroblasts and inflammatory mediators. The disease starts with acute inflammation between the layers of the tunica albuginea. The complete process to substitute fibrin in the tunica albuginea takes 12–18 months when the curvature is completely formed.
2. Endocrine imbalance: the disease develops because of a hormonal imbalance.
3. Connective tissue pathology: connective tissue pathology (Dupuytren's contracture, scleroderma, subacromial bursitis, dermatomyositis, and sclerosis of the auricles) related to other diseases is noted. The chromosomal abnormalities of cells taken from plaques in Peyronie's disease are similar to those in Dupuytren's contracture.
4. Toxic chemicals: there is a link between the development of Peyronie's disease and the prolonged intake of barbiturates.
5. Genetic associations: class II antigens of the human leukocyte antigen (HLA) system are frequently detected in Peyronie's disease, particularly HLA-DR3 and HLA-DQW2. These antigens are associated with organ-specific autoimmune disorders and resemble the rheumatic process.
6. Viral changes: the transformation factor TGF- β_1 (cytokine) enhances the synthesis and accumulation of collagen in the cavernous tissue of the penis and stimulates the growth of fibroblasts, thus leading to a decrease in nitric oxide, as well as hypoxia and damage to the endothelium.
7. Vegetative theory: a lesion of autonomic cavernous innervation occurs in the zone of the dorsal vascular–neural bundle.

In the pathogenesis of Peyronie's disease, the development of fibrosis of the tunica albuginea or cavernous tissue is important because this type of fibrosis may be one of the causes of erectile dysfunction. The congenital anatomical features of the penis (e. g., chordee with

connective tissue bands) and urethral diseases (hypospadias, stricture) may increase the risk of Peyronie's disease.

The involvement of the Buck fascia, perforating vessels, and dorsal arteries of the penis leads to penile venous occlusion disruption and arterial insufficiency, which require dynamic cavernosography. The dorsal, lateral, and ventral parts of the penis are often involved in the scarring. Given the deposition of calcium salts in the indurated areas, a cartilaginous consistency is acquired. Plaques in connective tissue appear on the rear surface of one or both cavernous bodies in the form of a flat polygonal formation that grows downward and inward; one or more of these fibrous plaques may be present.

In the diagnosis of Peyronie's disease, magnetic resonance imaging or computed tomography is used. The ultrasound dopplerography of the penis assesses the size and localization of plaques and measures the blood flow in the vessels of the penis. Conservative treatment is indicated at the early stages of the disease and in cases wherein the patient refused surgical treatment [8–10]. Conservative treatment is usually performed in the first year after the onset of the disease to the onset of plaque calcification and when the penis curvature is less than 30–45 degrees. Some of the treatments include hormonal drugs, biogenic stimulants, physiotherapy methods, shockwave therapy, close-focus roentgenotherapy, verapamil, interferons, and type 5 phosphodiesterase (PDE5) inhibitors [11–13].

The goal of this study was to evaluate the efficacy of the conservative treatment of Peyronie's disease.

MATERIALS AND METHODS

A total of 27 men aged 25 to 66 years old (mean age 45.5 years) received conservative treatment for Peyronie's disease at Alexandrovsky Hospital, which is the headquarters of the Department of Urology of I.I. Mechnikov North-West State Medical University. The duration of the disease was from three months to five years. All patients were married. Four patients had a history of Dupuytren's contracture and two patients had controlled diabetes mellitus. Patients reported moderate pain in the penis, a reduction in adequate and spontaneous erections, and mild induration in the body (e. g., the root of the penis), which causes a slight curvature in the penis and worsens the quality of their life.

All patients underwent general urinary examination. Urinalysis, clinical examinations, and biochemical

blood tests were performed. The levels of sexual and gonadotropic hormones and the level of prostate specific antigen (PSA) in serum were determined. The levels of sexual and gonadotropic hormones and serum glucose were normal, whereas PSA levels were below 2 ng/ml. Additionally, sexually transmitted infections were ruled out in all patients.

The examination included the ultrasound dopplerography of the penis, velocity of blood flow in the cavernous and dorsal arteries and the size of the plaques were determined. The size of the plaques of the penis did not exceed 1.5 cm in diameter and the angle of curvature of the penis was less than 45 degrees, which was the criteria for inclusion in this study.

All patients received combined therapy with symptomatic, immunological, and physiotherapeutic treatments. The latter included magnetic-laser therapy on the plaque area of the penis and local negative pressure (LNP) therapy. Fifteen patients (Group 1) also received Longidaza preparation (3,000 IU intramuscularly once every 3 days (10 injections) with the simultaneous administration of rectal suppositories with Longidaza at the same dose (10 suppositories)). Phonophoresis to the plaque area with Longidaza was prescribed locally to these patients (10 sessions), along with magnetic-laser therapy. The remaining 12 patients (Group 2) did not receive Longidaza.

Patients in both groups were simultaneously treated with magnetic-laser therapy by using the AMVL-01 device, which creates an LNP at 2 atm in the flask and causes an erection with 10–20 min duration (Figure 1).

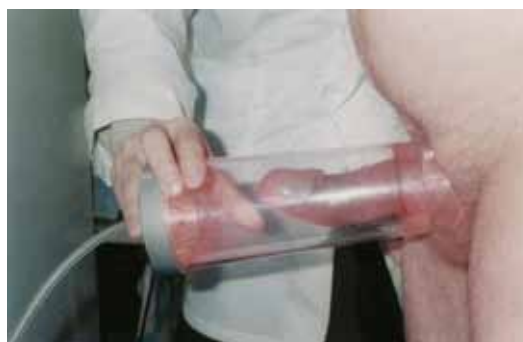

Fig. 1. Diagnosis of the curvature of the penis using the AMVL-01 vacuum laser therapeutic urological device in Patient A (54 years old with Peyronie's disease). LNP with maximum discharge in the flask affects the baro- and thermoreceptors of the skin of the penis, thus enhancing microcirculation in its vessels. An insignificant curvature (30-degree angle of curvature) of the penis was noted

Рис. 1. Диагностика искривления полового члена на аппарате АМВЛ-01 (аппарат вакуумно-лазерный терапевтический урологический) у больного А., 54 года, с болезнью Пейрони. Локальное отрицательное давление с максимальным разряжением в колбе воздействует на баро- и терморецепторы кожи полового члена, усиливает микроциркуляцию в его сосудах. Выявлено незначительное искривление (угол искривления — 30 градусов) полового члена

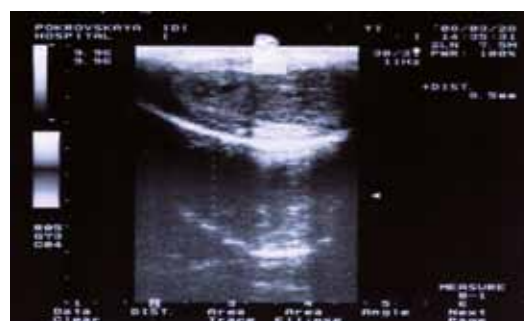The LNP therapy included 10 procedures. In severe erectile dysfunction, a PDE5 inhibitor was prescribed in individually selected doses. The results of treatment were evaluated 6 and 12 months after its onset.

The data were analyzed with conventional statistical methods by using SPSS12.0 software. The mean value was calculated, and the confidence coefficient was $\alpha = 0.95$ (probability of error $p < 0.05$).

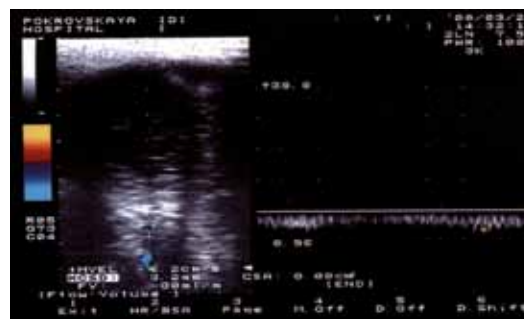RESULTS

In performing ultrasound dopplerography on the penis, vascular changes were detected in 16 of the 27 patients examined, and 8 patients (50%) had manifestative venogenic compensated and subcompensated erectile dysfunction (Figures 2 and 3). The remaining 11 patients had no signs of vascular changes (Table 1).

In all 27 patients, the maximum size of the plaques before treatment was less than 1.5 cm. In 13 patients (48.1%), the plaques were >0.5 cm in diameter. Six patients (22.2%) had plaques of >1 cm, and the remaining eight patients (29.6%) had plaques of <0.5 cm in diameter (Table 2). In Group 1, the maximum plaque sizes were <0.5 , >0.5 , and >1 cm in five, seven, and three patients, respectively; in Group 2, the same plaque categories were found in three, six, and three patients, respectively. Six months



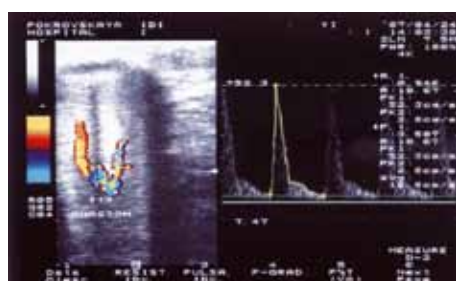
a



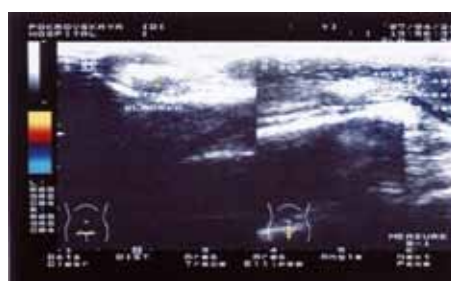
b

Fig. 2. Ultrasound dopplerography of the penis of Patient D (36 years old with Peyronie's disease and venogenic erectile dysfunction): a) in the distal part of the penis, the plaques are from 1–2 to 8.5 mm; b) the dorsal vein did not collapse, and blood flow along it was 30 ml/min. Valsalva test was positive

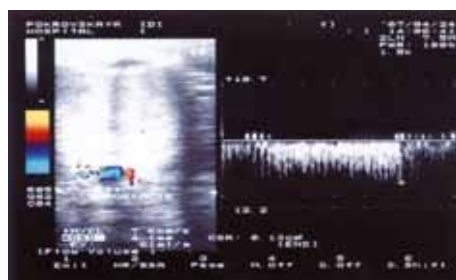
Рис. 2. Ультразвуковая доплерография полового члена больного Д., 36 лет, с болезнью Пейрони и веногенной эректильной дисфункцией: а — в дистальной части полового члена бляшки от 1–2 до 8,5 мм; б — дорсальная вена не спалась, кровоток по ней определяется в течение всего исследования до 30 мл/мин. Проба Вальсальвы положительная



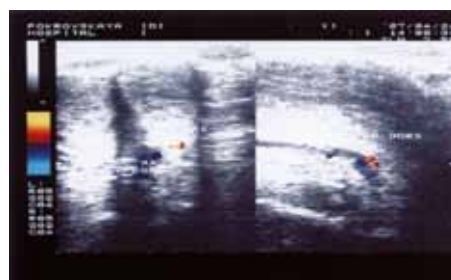
a



b



c



d

Fig. 3. Ultrasound dopplerography of the penis of Patient T (55 years old with Peyronie's disease and venogenic erectile dysfunction). The patient has Dupuytren's contracture: a) abnormality of the structure of the cavernous arteries, i.e., anastomosis of the cavernous arteries in the crus of the penis; b) plaques in the cavernous bodies (plaque of 11.4 mm \times 4.6 mm \times 9.2 mm is marked), which deformed the penis; c) and d) noncollapse concurrence of the dorsal vein as a sign of venous erectile dysfunction

Рис. 3. Ультразвуковая доплерография полового члена больного Т., 55 лет, с болезнью Пейрони и веногенной эректильной дисфункцией. У больного выявлена контрактура Дюпюитрена: а — аномалия строения кавернозных артерий: в ножке полового члена кавернозные артерии имеют анастомоз; б — бляшки в кавернозных телах (выделена бляшка размером 11,4 \times 4,6 \times 9,2 мм), деформирующие половой член; с и d — неспадение дорсальной вены — признак веногенной эректильной дисфункции

Table 1

Vascular disorders in patients with Peyronie's disease by the ultrasound dopplerography of the penis

Таблица 1

Сосудистые нарушения у больных с болезнью Пейрони по данным ультразвуковой доплерографии полового члена

Group of patients	Vascular abnormalities by the ultrasound dopplerography of the penis	
	Detected	Undetected
1 (n = 15)	9	6
2 (n = 12)	7	5
Total (n = 27)	16 (59,3%)	11 (40,3%)

Table 2

Results of treatment of patients with Peyronie's disease (n = 27)

Таблица 2

Результаты лечения пациентов с болезнью Пейрони (n = 27)

Group of patients	Maximum size of plaques according to ultrasound dopplerography, cm									No plaques 6 and 12 months, n (%)
	Before treatment			Six months after the treatment			Twelve months after the treatment			
	< 0.5	> 0.5	> 1	< 0.5	> 0.5	> 1	< 0.5	> 0.5	> 1cm	
1 (n = 15)	5	7	3	1	4	2	–	3	1	8 (66.6%)/ 11 (73.3%)
2 (n = 12)	3	6	3	2	4	2	1	3	2	4 (33.3%)/ 6 (50%)
Total (n = 27)	8	13	6	2	7	4	1	6	3	14 (51.8%)/ 17 (63%)

after the start of the complex combined treatment with Longidaza, the number of patients with plaques of more than 0.5 cm (before treatment in 13 patients and after treatment in 7 patients) was reduced by almost twofold. The number of patients with plaques less than 0.5 cm decreased fourfold. The absence of plaques was achieved 6 months after the start of treatment in 8 patients (53.3%) in Group 1 and 4 patients (33.3%) in Group 2 and 12 months after the treatment in 11 (73.3%) in Group 1 and 6 (41.6%) patients in Group (see Table 2).

The results of the study reveal the efficacy of conservative complex therapy at the early stage of the disease, as well as the pathogenetic justification of the treatment and its good tolerability. At the same time, the effectiveness of treatment was higher in the group of patients receiving Longidaza.

CONCLUSIONS

Conservative therapy in Peyronie's disease is effective in patients at the early stages of the disease, with moderate deviation of the penis and plaques of up to 1.5 cm. The inclusion of Longidaza in the complex therapy increases the treatment efficacy.

REFERENCES

- Щеплев П.А., Гарин Н.Н., Данилов И.А., и др. Болезнь Пейрони. – М.: ИД «АБВ-пресс», 2012. [Shheplev PA, Garin NN, Danilov IA, et al. *Bolezni' Pejroni*. Moscow: ABV-press; 2012. (In Russ.)]
- Урология. Российские клинические рекомендации / Под ред. Ю.Г. Аляева, П.В. Глыбочко, Д.Ю. Пушкаря. – М.: ГЭОТАР-Медиа, 2015. [Urologija. Rossijskie klinicheskie rekomendacii. Ed. by Yu.G. Aljaev, P.V. Glybochko, D.Yu. Pushkar. Moscow: GEOTAR-Media; 2015. (In Russ.)]
- Sommer F, Schwarzer U, Wassmer G, et al. Epidemiology of Peyronie's disease. *International Journal of Impotence Research*. 2002;14(5):379-383. doi: 10.1038/sj.ijir.3900863.
- La Pera G, Pescatori ES, Calabrese M, et al. Peyronie's disease: prevalence and association with cigarette smoking: a multicenter population-based study in men aged 50-69 years. *European Urology*. 2001;40(5):525-530. doi: 10.1159/000049830.
- Щеплев П.А., Данилов И.А., Колотинский А.Б., и др. Клинические рекомендации. Болезнь Пейрони // Андрология и генитальная хирургия. – 2007. – № 1. – С. 55–58. [Shheplev PA, Danilov IA, Kolotinskij AB, et al. *Klinicheskie rekomendacii. Bolezn' Pejroni. Andrologija i genital'naja hirurgija*. 2007;(1):55-58 (In Russ.)]
- Калинина С.Н., Тиктинский О.Л., Новиков И.Ф. Фибропластическая индурация полового члена (болезнь Пейрони): Пособие

- для врачей-урологов. — СПб.: Изд-во СПбМАПО, 2009. [Kalinina SN, Tiktinskij OL, Novikov IF. Fibroplasticheskaja induracija polovogo chlena (bolezni' Pejroni). Posobie dlja vrachej-urologov. Saint Petersburg: SPbMAPO; 2009. (In Russ.)]
7. Тиктинский О.Л., Калинина С.Н., Михайличенко В.В. Андрология. — М.: МИА, 2010 [Tiktinskij OL, Kalinina SN, Mihajlichenko VV. Andrologija. Moscow: MIA; 2010. (In Russ.)]
 8. Мазо Е.Б., Муфагед М.Л., Иванченко Л.П., и др. Консервативное лечение болезни Пейрони в свете новых патогенетических данных // Урология. — 2006. — № 2. — С. 31–37 [Mazo EB, Mufaged ML, Ivanchenko LP, et al. Konservativnoe lechenie bolezni Pejroni v svete novyh patogeneticheskikh dannyh. *Urologija*. 2006;(2):31-37. (In Russ.)]
 9. Adeniyi AA, Goorney SR, Pryor JP, Ralph DJ. The Lue procedure: an analysis of the outcome of Peyronie's disease. *BJU Int*. 2002;89(4):404-408. doi: 10.1046/j.1464-4096.2001.01896.x.
 10. Levine LA, Goldman KE, Greenfield JM. Experience with intra-plaque injection of Verapamil for Peyronie's disease. *J Urol*. 2002;168(2):621-625. doi: 10.1097/00005392-200208000-00045.
 11. Москалева Ю.С., Остапченко А.Ю., Корнеев И.А. Болезнь Пейрони // Урологические ведомости. — 2015. — Т. 5. — № 4. — С. 30–35 [Moskaleva YuS, Ostapchenko AYU, Korneev IA. Peyronie's disease. *Urologicheskie vedomosti*. 2015;5(4):30-35. (In Russ.)]
 12. Соколышник М.М., Гагарина С.В., Петрович Р.Ю., и др. Лечение эректильной дисфункции у пациентов с пластической индурацией полового члена // Урология. — 2008. — № 1. — С. 41–44. [Sokol'shhik MM, Gagarina SV, Petrovich RJU, et al. Lechenie jerektil'noj disfunkcii u pacientov s plasticheskoy induraciej polovogo chlena. *Urologija*. 2008(1):41-44. (In Russ.)]
 13. Leuret T, Loison G, Herve JM, et al. Extracorporeal shock wave therapy in the treatment of Peyronie's disease: experience with standard lithotripter (Siemens-Multiline). *Urology*. 2002;59(5):657-661. doi: 10.1016/s0090-4295(02)01527-3.

Information about the authors:

Svetlana N. Kalinina — Doctor of Medical Science, Professor, Urology Department. North-Western State Medical university named after I.I. Mechnikov, Saint Petersburg, Russia. E-mail: kalinina_sn@mail.ru.

Vladimir N. Fesenko — Candidate of Medical Science, Associate Professor, Urology Department. North-Western State Medical university named after I.I. Mechnikov, Saint Petersburg, Russia. E-mail: fesvn_spb@mail.ru.

Anton V. Nikolskii — Candidate of Medical Science, Urologist, Department of Urology. Aleksandrovskaya Hospital, Saint Petersburg, Russia.

Oleg O. Burlaka — Candidate of Medical Science, Head of Department of Urology. Aleksandrovskaya Hospital, Saint Petersburg, Russia. E-mail: burlaka@list.ru.

Natalia V. Marchenko — Head of Department of Physiotherapy. Aleksandrovskaya Hospital, Saint Petersburg, Russia.

Сведения об авторах

Светлана Николаевна Калинина — д-р мед. наук, профессор кафедры урологии. ФГБОУ ВО «Северо-Западный государственный медицинский университет им. И.И. Мечникова» Минздрава России, Санкт-Петербург. E-mail: kalinina_sn@mail.ru.

Владимир Николаевич Фесенко — канд. мед. наук, доцент кафедры урологии. ФГБОУ ВО «Северо-Западный государственный медицинский университет им. И.И. Мечникова» Минздрава России, Санкт-Петербург. E-mail: fesvn_spb@mail.ru.

Антон Валерьевич Никольский — канд. мед. наук, врач-уролог отделения урологии. СПб ГБУЗ «Александровская больница», Санкт-Петербург.

Олег Олегович Бурлака — канд. мед. наук, заведующий отделением урологии. СПб ГБУЗ «Александровская больница», Санкт-Петербург. E-mail: burlaka@list.ru.

Наталья Владимировна Марченко — заведующая отделением физиотерапии. СПб ГБУЗ «Александровская больница», Санкт-Петербург.